

**Jiří Stehlík  
Jan Štulík et al.**

# **CALCANEAL FRACTURE**



**KAROLINUM  
GALÉN**

## Partners



**Jiří Stehlík  
Jan Štulík et al.**

# **CALCANEAL FRACTURE**



  
NAKLADATELSTVÍ  
UNIVERZITY KARLOVY

  
GALEN

### **Authors**

Ass. Prof. Jiří Stehlík, MD, PhD  
*Hospital České Budějovice, Orthopaedic Department*

Ass. Prof. Jan Štulík, MD, PhD  
*Charles University Prague, 2<sup>nd</sup> Faculty of Medicine and University Hospital Motol, Department of Spinal Surgery*

### **Coauthors**

Professor Petr Havránek, MD, PhD  
*Charles University Prague, 2<sup>nd</sup> Faculty of Medicine and Thomayer University Hospital, Department of Child Surgery and Traumatology*

Ass. Prof. Miroslav Tvrdek, MD  
*Charles University Prague, 3<sup>rd</sup> Faculty of Medicine and University Hospital Královské Vinohrady, Department of Plastic Surgery*

### **Reviewers**

Ass. Prof. Martin Krbec, MD, PhD  
*Masaryk University in Brno, Faculty of Medicine and University Hospital Brno, Orthopaedic Department*

Jaroslav Vich, MD  
*Hospital Kladno, Department of Orthopaedics and Traumatology*

Stanislav Taller, MD  
*Hospital Liberec, Traumatology Centre*

### **Jiří Stehlík, Jan Štulík et al. CALCANEAL FRACTURE**

Published by Galén Publishing House, Na Bělidle 34, Prague 5  
and Charles University in Prague, The Karolinum, Ovocný trh 3, Prague 1  
Editor-in-Chief Lubomír Houdek, MA  
Vice-rector prof. PhDr. Ivan Jakubec, CSc.  
Responsible Editor Mgr. Jana Jindrová  
Documentation from the authors' archives

Typesetting Mgr. Kateřina Dvořáková, Galén  
Print GLOS, Špidlenova 436, 513 01 Semily  
Intended for specialist public  
First edition  
G 281076

**www.galen.cz**

**www.cupress.cuni.cz**

*All rights reserved.*

*No part of this book may be reproduced in any form by any electronic or mechanical means (including photocopying or recording) without permission in writing by publisher. Authors, organizers and publisher have made every effort to ensure that information about medical products correspond to the latest knowledge available at the time of preparing the work. The publisher is not responsible for the use of these products and recommends to follow the manufacturers' product information and package inserts, including contraindications, dosages and precautions. This applies particularly to rarely used or newly marketed medical products.*

*The text contains trademarks of medical and other products. Absence of trademark symbols (®, TM etc.) shall not mean that the trademarks are not protected.*

© Galén, 2010

**ISBN 978-80-246-1798-5 (Karolinum)**

**ISBN 978-80-7262-659-5 (Galén)**

# CONTENTS

<b>FOREWORD</b> .....	7
<b>1. INTRODUCTION</b> .....	9
<b>2. ANATOMY</b> .....	11
2.1. Bone anatomy .....	11
2.2. Topographical anatomy .....	13
■ Lateral surface .....	13
■ Medial surface .....	14
■ Inferior surface .....	15
2.2.1. Topographic notes .....	16
2.2.2. Anatomical spaces .....	16
2.2.3. Anatomical relations .....	17
2.3. Pathoanatomy of fractures .....	18
2.3.1. Intra-articular fractures .....	19
2.3.2. Extra-articular fractures .....	23
<b>3. DIAGNOSTICS</b> .....	25
3.1. Case history .....	25
3.2. Clinical examination .....	25
3.3. Radiographic diagnosis .....	26
3.3.1. Conventional radiographic examination .....	26
■ Intra-articular structures .....	26
■ Extra-articular structures .....	27
■ Landmarks and angles .....	28
■ Internal structure .....	29
3.3.2. Classic tomography .....	29
3.3.3. Computed tomographic scanning .....	31
■ CT scanning .....	31
■ CT scan of fracture .....	31
3.3.4. Options of radiographic evaluation of bone structures in individual projections .....	32
<b>4. CLASSIFICATIONS</b> .....	35
4.1. Classifications Based on Conventional Radiographs .....	35
4.1.1. Böhler classification .....	35
4.1.2. Watson-Jones classification .....	36
4.1.3. Essex-Lopresti classification .....	36
4.1.4. Warrick and Bremner classification .....	37
4.1.5. Rowe classification .....	38
4.1.6. Wondrák classification .....	38
4.1.7. Soeur and Remy classification .....	38
4.1.8. McReynolds classification .....	39
4.1.9. Ross and Sowerby classification .....	39
4.2. Classifications based on computed tomography scanning .....	39
4.2.1. Zwipp classification .....	39
4.2.2. Crosby and Fitzgibbons classification .....	40
4.2.3. Sanders classification .....	40
4.2.4. Eastwood classification .....	41
4.3. Authors' own classification .....	42
<b>5. THERAPY</b> .....	45
5.1. Nonoperative treatment .....	45
5.1.1. History .....	45
5.1.2. Present state of the art .....	45
5.2. Operative treatment .....	46
5.2.1. History .....	46
5.2.2. Present state of the art .....	47
■ Lateral surgical approach (Palmer) .....	47
■ Medial surgical approach (McReynolds) .....	49
■ Bone defect .....	50
■ Cartilage damage .....	51
5.2.3. Postoperative treatment .....	52
<b>6. AUTHORS' OWN OPERATIVE METHOD</b> .....	55
6.1. Diagnosis .....	55
6.2. Indication .....	55
6.2.1. Aim of the method .....	55
6.2.2. Technical equipment .....	55
6.3. Operative technique .....	56
6.4. Postoperative treatment .....	60
6.5. Group of patients .....	60
6.6. Evaluation .....	61
6.7. Results .....	61
6.8. Discussion .....	64
<b>7. COMPLICATIONS</b> .....	73
7.1. Complications caused by trauma .....	73

7.1.1. Soft tissue injuries . . . . .	73	8.1.3. Inability to close the surgical wound . . . . .	86
7.1.2. Complicated and non-standard types of fractures . . . . .	73	8.1.4. Postoperative wound breakdown . . . . .	86
7.2. Iatrogenous causes . . . . .	74	8.2. Late defects . . . . .	89
7.2.1. Wrong indication . . . . .	74	8.2.1. Osteomyelitis . . . . .	89
7.2.2. Unsuitable method . . . . .	74	8.2.2. Reconstruction for unstable skin cover . . .	90
7.2.3. Lack of knowledge of the method . . . . .	74	<b>9. CALCANEAL FRACTURES IN CHILDREN. . . . .</b>	<b>93</b>
7.3. Early complications . . . . .	76	9.1. Incidence . . . . .	93
7.3.1. Compartment syndrome. . . . .	76	9.2. Development and anatomy . . . . .	93
7.3.2. Acute infection . . . . .	79	9.3. Aetiology . . . . .	94
7.4. Late complications . . . . .	79	9.4. Diagnostics . . . . .	97
7.4.1. Algoneurodystrophic syndrome. . . . .	79	9.5. Forms of calcaneal fractures in children and their classification . . . . .	98
7.4.2. Healing in displacement . . . . .	79	9.5.1. Acute fractures . . . . .	98
7.4.3. Nonunion . . . . .	81	9.5.2. Occult and fatigue fractures . . . . .	99
7.4.4. Chronic osteomyelitis . . . . .	81	9.5.3. Physeal injury to the calcaneal apophysis . . . . .	99
7.5. Prevention . . . . .	81	9.5.4. Dislocation in the pericalcaneal region . . .	99
<b>8. COMPROMISED SOFT TISSUE HEALING . . . . .</b>	<b>83</b>	9.6. Therapy . . . . .	99
8.1. Early defects . . . . .	83	9.6.1. Treatment of acute fractures of the calcaneal body . . . . .	99
8.1.1. Early defects caused by the impact without bone defect . . . . .	83	9.6.2. Treatment of fatigue fractures and injuries to the physis of the ossification nucleus of the tubercle .	100
■ Medial plantar flap . . . . .	83	9.6.3. Procedure recommended by the author . .	101
■ Medialis pedis flap . . . . .	84	9.7. Complications and sequelae . . . . .	104
■ Lateral supramalleolar flap . . . . .	84	<b>10. CONCLUSION . . . . .</b>	<b>107</b>
■ Sural flap . . . . .	85		
■ Abductor flap . . . . .	86		
8.1.2. Early defects caused by the impact in combination with a bone defect . . . . .	86		

## FOREWORD

Fractures of the calcaneus are as old as humankind, as demonstrated by findings on prehistoric bones.

An exhaustive historical overview of this issue was presented by Edward Wondrák in his monograph »Fractures of the Calcaneus«. Let me therefore mention only a few historical facts and milestones in the treatment of these fractures.

In 5th–4th century B.C., Hippocrates gathered remarkable knowledge and findings and published in his collection of works in the chapter »On fractures of the calcaneus« where he describes mechanism of the injury and development of haematoma, oedema and tenderness. He recommends treatment by ointments and linen fixation bandages that must be flexible and describes the danger of gangrene which he called »black heel« causing a »big subsequent wound«. He points out that the treatment is lengthy, tends to reverse and mentions also septic conditions and the importance of positioning the affected limb. Hippocrates' work was partly translated and summarized by Wondrák, similarly as the Saličet's »Barber-surgery« published in the Middle Ages (Verona, 1275). Saličet recommended to use a "cast" made from linen, oakum and wood to be fixed by linen bandages on fractures. Renaissance brought new findings. In the Vesalius's anatomy (Venice, 1568) we find a complete description of the calcaneus. At that time the fractures were treated by linen fixation bandages. Reports preserved from those times show that the knowledge and experience of the ancient times gathered by Hippocrates were forgotten. At the turn of 17th century the interest in calcaneal started to grow again. Development in this field was significantly prompted by J. F. Malgaigne (1847) who in his book »Traité des fractures et luxations« gives a precise description of the calcaneal fractures. He divides these fractures into two types according to their mechanism – fractures caused by impact, comminution (par écrasement) and avulsion (par arrachement). He sets also the therapeutic principles, namely application of wound compresses for 4–6 weeks and only then to fix the limb in a bandage. Discovery of x-rays in 1895 brought a revolutionary change in the diagnostics and

treatment of the calcaneal fractures. Radiographic examination was the first to provide an objective view of the calcaneal fractures.

History shows the twists and turns of the development of treatment of calcaneal fractures, with nonoperative and operative procedures alternating. The person who showed the direction and introduced a system in nonoperative therapy was Lorenz Böhler. In 1929, he introduced a classification dividing the calcaneal fractures into eight groups. The Böhler's angle (Tubergelenkwinkel) indicated deformation of the calcaneus in comminuted fractures. For reduction Lorenz Böhler used a traction device with a Kirschner wire driven through the calcaneus and the Phelps-Gocht apparatus for lateral compression and reduction of the displaced fragments. He also accepted reduction of the calcaneus with a Steinmann pin inserted into the fragment of the calcaneus (Westhues, 1934). The mentioned procedures were not able to reduce the calcaneal fractures involving the talocalcaneal articulation and subtalar arthrodesis was often inevitable in the second step. Another milestone is represented by the achievements of the French school with its main protagonist R. Leriche (1913, 1935) whose method consisted in open reduction, bone grafting and fixation of fractures by screws. These concepts have been gradually implemented as a therapeutic algorithm only in the recent 15 years. In 1952, Essex-Lopresti developed a simple classification of the calcaneal fractures. His concepts were used by Wondrák who published his classification in the textbook »Fractures of the calcaneus« (1964). This book influenced significantly the development of treatment of these fractures in the Czech Republic. Of the Czech authors we should mention in this context also A. Ondrouch (1963) who replaced the calcaneus by the Austin Moore endoprosthesis.

Another milestone in the development of diagnostics of the calcaneal fractures was introduction of CT scanning. A significant contribution to this development was made by the Hanover school in the eighties of 20<sup>th</sup> century (Zwipp, Tscherne). Evaluation of radiographs and CT scans as well as postoperative use of the image

intensifier created conditions for open reduction of intra-articular fractures of the calcaneus with the subsequent plate osteosynthesis. It should be noted that at the beginning these operations were often associated with infections. Thanks to the cooperation with plastic surgeons their number has been significantly reduced. In spite of this, these operations should be entrusted only to specialized departments. At our Orthopaedic Department we have been treating calcaneal fractures since its foundation in 1984. In addition to standard procedures based on the Böhler's school and the Wondrák's works, we introduced also the Omoto's method consisting in manual reduction of the calcaneus, positioning of the limb, its icing and functional treatment. The subsequent painful talocalcaneal joint in the procedure sometimes required subtalar arthrodesis.

In 1993, Stehlík started to use his own method of reduction and stabilization of the calcaneal fractures in-

volving the subtalar joint and their fixation by Kirschner wires under image intensifier.

The authors of this monograph present a well conceived method of the treatment of intra-articular fractures of the calcaneus by closed procedure verified on the clinical material from the period of 1994–2001 (302 fractures in 261 patients). The monograph provides a clear therapeutic guide. On the basis of their own classification of these fractures (evaluation of standard radiograph + CT scanning) they have devised a procedure of reduction, stabilization and postoperative final management. Highly valuable is the chapter dealing with complications requiring cooperation with plastic surgeon.

The monograph offers the readers a differentiated overview of the current trend of treatment of the calcaneal fractures and contributes to their diagnostics and therapy in the clinical practice.

*Oldřich Čech*



# 1. INTRODUCTION

Calcaneal fractures constitute one of the most contradictory chapters of traumatology of the musculoskeletal apparatus. No other type of fracture is associated with such a wide range of different views regarding its management. Lack of consensus is documented also by the fact that so far about 140 therapeutic methods have been suggested for its treatment. On the one hand, authors question the very sense of treatment of such fractures, not recommending even an attempt at reduction or fixation, which however, often results in severe sequelae. On the other hand, there are supporters of radical open reduction and internal fixation performed simultaneously from two surgical approaches. There are only a few locations in traumatology of the musculoskeletal apparatus that are so sensitive as the calcaneus in terms of proper surgical technique. Even the most renowned clinical departments in Europe entrust this surgical intervention only to “heel specialists”. Despite very strict indication criteria for open reduction and internal fixation, the number of reported infections ranges between 5–20 %, and amputations of limbs are not an exception. These fractures are economically the most demanding of all fractures, with

the reported length of hospitalization of 32 days and the average period of sick leave up to 150 days! Our own unsatisfactory results of nonoperative treatment, concerns about possible complications resulting from open procedure and the need for a generally applicable method prompted us at the beginning of the nineties of 20th century to devise our own surgical method. Surprisingly good results after 8 years of its application as well as general interest in it inspired us to write the following lines.

We wish to thank our teacher Professor O. Čech, MD, DSc for a valuable advice and great support. We also wish to thank Associate Professor J. Šprindrich, MD, PhD, Emeritus Head of Department of Radiology and Diagnosis of the University Hospital in Prague, and his team for cooperation in diagnostics and preparation of documents and Professor J. Štingl, MD, DSc for comments on the section of anatomy. Special recognition is also due to our reviewers, senior consultant J. Vicha, MD, Associate Professor M. Krbec, MD, PhD and senior consultant S. Taller, MD as well as our colleagues Z. Krátký, MD, M. Held, MD, and E. Šťastný, MD.



## 2. ANATOMY

### 2.1. Bone anatomy

Of vital importance in the treatment of the calcaneal fractures is a profound knowledge of the anatomy of the calcaneus and its relation to the surrounding structures. A number of methods of treatment failed and subsequent complications developed primarily due to the lack of knowledge of complicated relations in this region.<sup>(2,12–15,28,30,39)</sup> It is recommended to examine anatomical specimens of the tarsus prior to commencement of any treatment. In addition, during the learning curve we always used a model of the calcaneus directly in the operating theatre to see the proper orientation of individual structures.

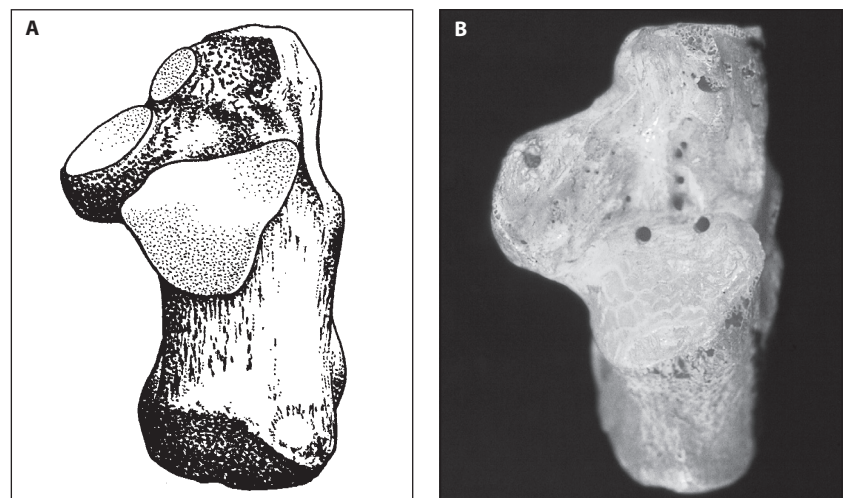
The calcaneus is the largest tarsal bone that forms the posterior, shorter part of the longitudinal arch of the foot. Its anterior half supports the talus serving to transmit the weight of the body from the tibia to the ground. In the opposite direction, i.e. from the sole, the calcaneus counteracts compressive forces exerted by the plantar muscles, ligaments and the aponeurosis. The calcaneus is formed by a thin cortical shell filled with cancellous bone, except for the calcaneal tuberosity having a condensed thickened cortex (Fig. 3.7.). The calcaneus is of irregular shape with six surfaces presenting four articular facets that ensure contact with the corresponding bones of the tarsus.

**The superior surface of the calcaneus** (Fig. 2.1.) carries the posterior, middle and anterior articular facets. These facets are of different shape and different inclination angle. They allow optimal transmission of load and mutual functional “cooperation” with articular facets of the talus.

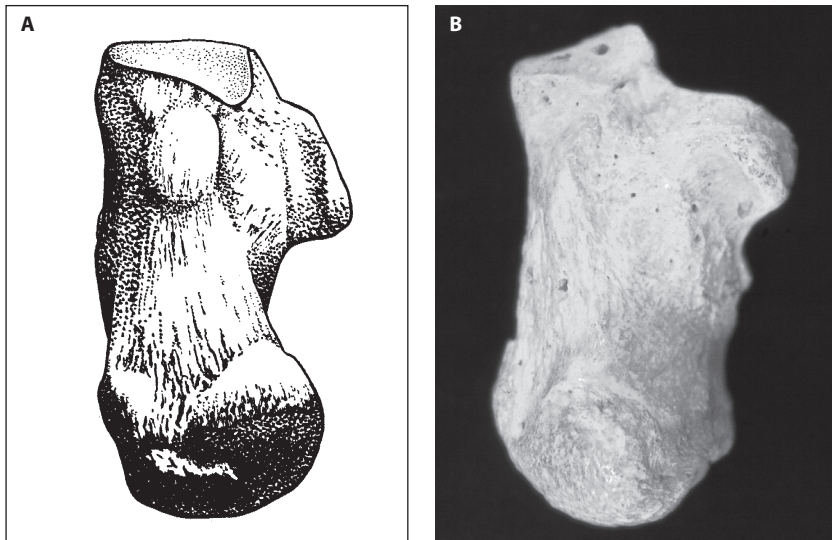
**The posterior articular facet** is the largest of them and clinically the most significant. Together with the corresponding articular surface of the talus it forms a separate joint and supports the body of the talus. From the middle and anterior articular facets it is separated by the calcaneal groove that at the same time forms the floor of the tarsal canal and sinus. The posterior articular facet is oval, convex and its long axis runs distally and laterally at about 45° to the sagittal plane.

**The middle articular facet** resting on the sustentaculum tali is concave, oval-shaped and articulates with the middle surface on the talar head and neck.

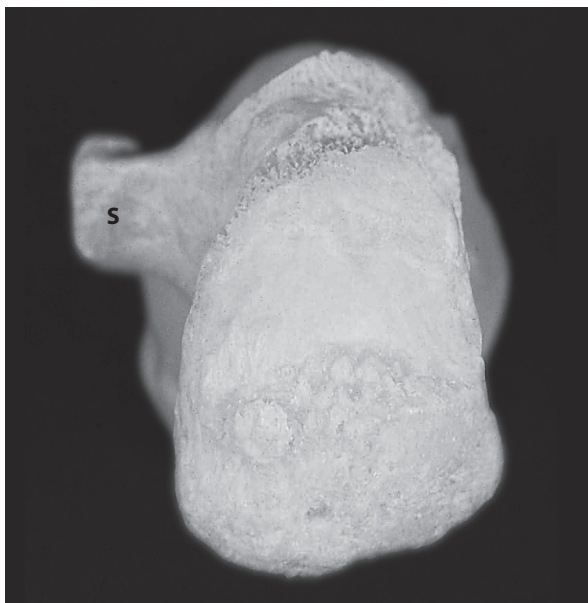
The posterior rim of the **anterior articular surface** forms the anterolateral border of the tarsal sinus (Fig. 2.14.) In this area, the stem of bifurcate ligament formed by the calcaneonavicular and calcaneocuboid ligaments is attached. The area lateral to the bifurcate ligament gives attachment to the inferior extensor ligament and the part of the origin of the extensor digitorum brevis. The middle and anterior articular surfaces may be united or separate



**Fig. 2.1. Superior surface of the calcaneus: A – schematic line drawing; B – anatomic specimen. Note: all specimens of the calcanei are shown from the right side**



**Fig. 2.2. Inferior surface of the calcaneus: A – schematic line drawing; B – anatomic specimen**



**Fig. 2.3. Posterior surface of the calcaneus, anatomic specimen**  
S – medially protruding sustentaculum tali

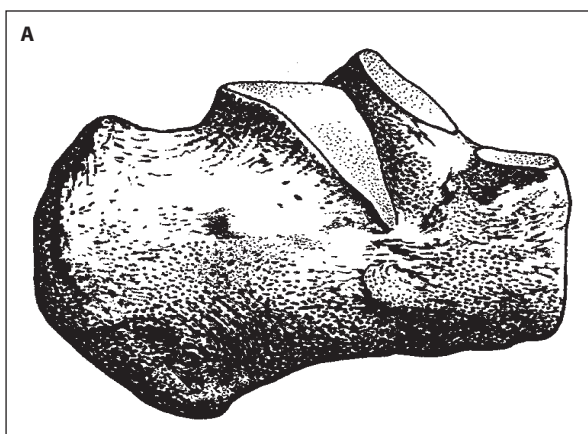
but they always have one common joint cavity and together with the spring ligament and deltoid ligament they act as a sling to support the head and neck of the talus.

**The inferior surface of the calcaneus** (Fig. 2.2.) is of a rectangular shape that gets wider and slightly convex towards the calcaneal tuberosity having a larger medial and smaller lateral processes. These processes of the tuberosity are designed to withstand the load from the hindfoot (the impact of heel strike) and at the same time they serve for the attachment of soft tissues. The lateral process gives attachment to the abductor digiti minimi of foot and the larger medial process to the abductor hallucis, the flexor digitorum brevis and the plantar aponeurosis.

**The anterior surface of the calcaneus** is fully articular, saddle-shaped ensuring articulation between the calcaneus and the cuboid.

**The posterior surface of the calcaneus** (Fig. 2.3.) has the shape of an inferiorly based triangle. The superior third is smooth, covered by a bursa separating it from the Achilles tendon inserting into the rough surface of the lower two thirds of the surface. The inferior third is the point of confluence of the plantar fascia and the Achilles tendon.<sup>(13,38)</sup>

**The lateral surface of the calcaneus** (Fig. 2.4.) continues with the lateral surface of the anterior calcaneal



**Fig. 2.4. Lateral surface of the calcaneus: A – schematic line drawing; B – anatomic specimen**

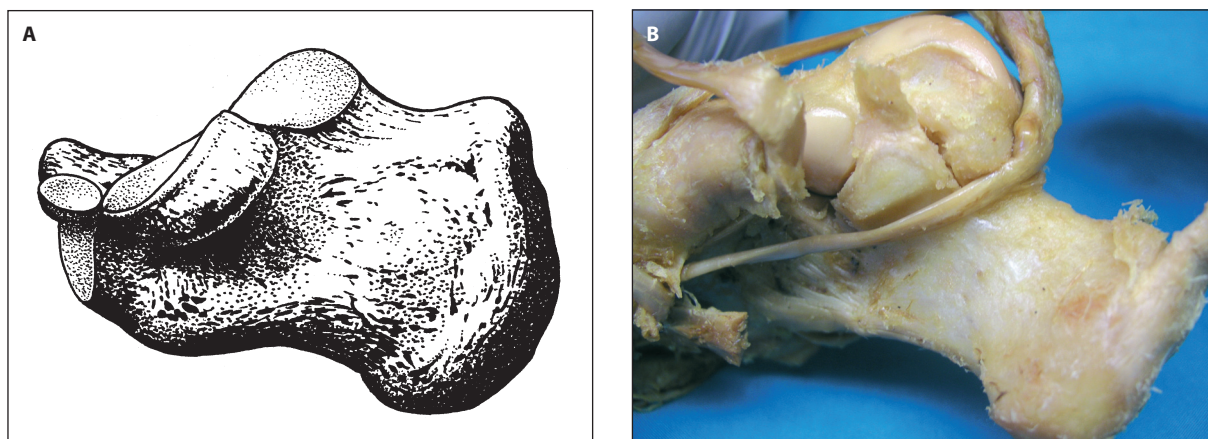


Fig. 2.5. Medial surface of the calcaneus: A – schematic line drawing; B – anatomic specimen

process carrying the anterior articular facet. The most protruding structure on the lateral surface, about 2 cm distal to the tip of the lateral malleolus is the peroneal trochlea. This bone tubercle serving as insertion for the inferior peroneal retinaculum divides the sheaths of the peroneal tendons into two parts. Tendons of the peroneus longus run posterior and inferior to the tendon of the peroneus brevis. The calcaneal tubercle located close behind and above the trochlea gives attachment to the calcaneofibular ligament. In the lower part, the lateral border of the calcaneal tuberosity is slightly projecting.

**The medial surface of the calcaneus** (Fig. 2.5.) is accentuated by the sustentaculum tali projecting medially from the distal part of its upper border forming the medial floor of the tarsal canal. The sustentaculum is the strongest structure on the medial side. This bone beak is excentrically loaded through the talus by compression forces transmitted from the lower limb.<sup>(9)</sup> Inferior to the sustentaculum, there is a groove for the tendon of the flexor hallucis longus. If the calcaneus is broken, this tendon obstructs fracture reduction. The sustentaculum tali serves also for the attachment of the tibiocalcaneal part of the deltoid ligament and partially for the calcaneonavicular ligament. In inferoposterior part of the medial surface, the medial process of the calcaneal tuberosity is significantly projecting.

## 2.2. Topographical anatomy

Any treatment of calcaneal fractures requires a detailed knowledge of topographic relations of individual structures to be treated or duly protected.<sup>(2,12,28,30)</sup> For practical reasons, the anatomical relations of individual parts are presented here with regard to the standard fracture lines, location of typical fragments and anatomical structures that may provide an easy and safe orientation in the surgical exposure of the calcaneus.

### ■ Lateral surface

**Skin cover** on the lateral surface of the calcaneus is thin, mobile but close to the sole becomes fixed toward the plantar surface of the foot.<sup>(30)</sup>

A dominant **bone structure** on the lateral surface is the calcaneal tuberosity, particularly its superior lateral corner which is easily palpable as we follow the Achilles tendon inferiorly to its insertion. At the lateral border of the Achilles tendon is the **sural nerve** that is usually located approximately 10 cm above the tip of the lateral malleolus. Damage to this nerve caused by unsuitable surgical approach or its entrapment by suture may result in persisting neurogenic pain. In its continuation the nerve contours the course of the peroneal tendons and passes 1–1.5 cm posterior to the lateral malleolus from which it is separated by the tendons (Fig. 2.6.). At the level of the tuberosity of the fifth metatarsal base, the sural nerve divides into its lateral and medial terminal branches.

**Blood supply to the lateral surface** is from three main sources. The posterior part is supplied by the calcaneal branches of the peroneal artery, the middle part by the anterior lateral malleolar artery (territory supplied by the anterior tibial artery) and the anterior part by the lateral tarsal artery (territory supplied by the dorsalis pedis artery) (Fig. 2.7.). The arteries are mutually interconnected forming a chain of anastomosing blood vessels arching approximately from the insertion of the Achilles tendon almost as far as the fifth metatarsal base. An interesting and quite important fact is that no interconnections have been found between the terminal branches of the mentioned arteries and minor arteries of the foot sole.

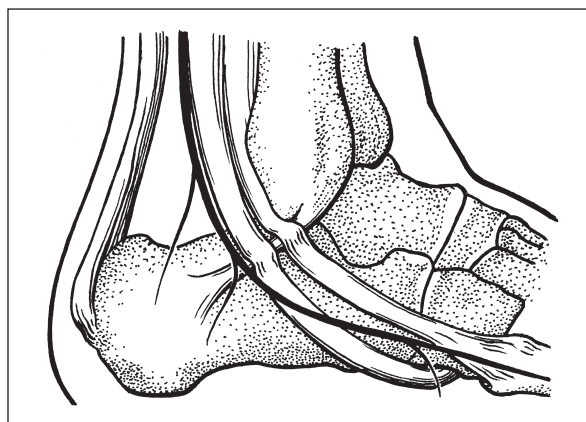
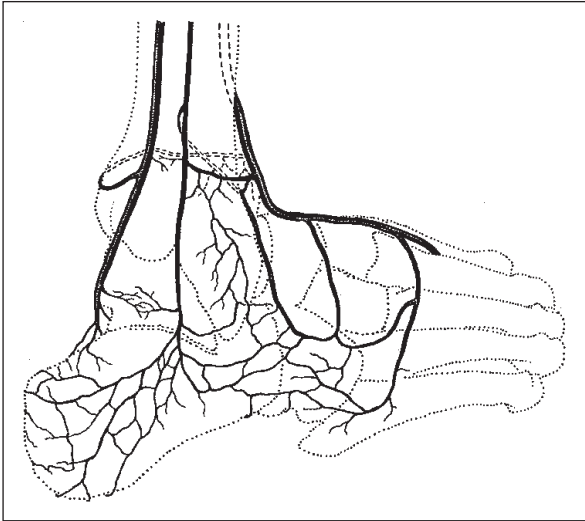


Fig. 2.6. Schematic line drawing of the course of the sural nerve



**Fig. 2.7. Schematic line drawing of blood supply of the lateral and posterior aspects of the foot**

**Peroneal tendons** course posterior to the fibula or posterior and inferior to the lateral malleolus and their posterior fibres parallel the sural nerve in the distance of 1.5 cm from the posterior border of the lateral malleolus. The peroneus brevis tendon runs anterior and superior to the peroneus longus tendon to its insertion on the fifth metatarsal base. Both tendons pass over the calcaneofibular ligament in their own sheaths attached in the region of the peroneal trochlea by means of the inferior fibular retinaculum.<sup>(34)</sup>

The main structure of the **lateral ligaments** of the ankle is the centrally located calcaneofibular ligament running from the tip of the lateral malleolus towards the calcaneal tuberosity and forming with the anterior talofibular ligament in the sagittal plane an angle of 70–140°<sup>(20)</sup> (Fig. 2.8.). Both the insertions of the two ligaments and the peroneal tendon sheaths may be disrupted during

a fracture of the lateral surface of the calcaneus which may cause lateral instability of the ankle.

#### ■ Medial surface

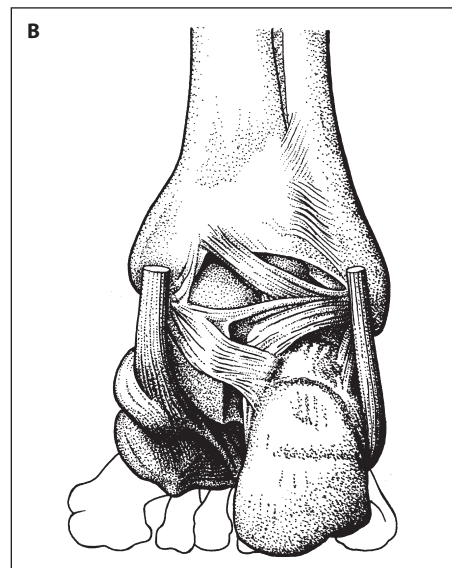
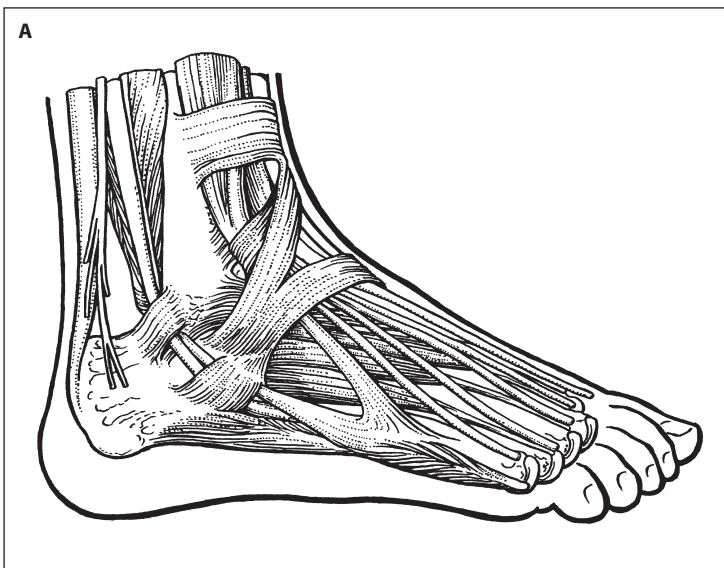
**Skin cover** on the medial surface is fixed to the superficial layer of the subcutaneous tissue and as compared to the lateral surface it is significantly less mobile.<sup>(30)</sup> Located deeper is a fibrofatty tissue layer, the abductor hallucis and the medial head of the quadratus plantae muscle. Subcutaneous tissue is arranged in layers with the superficial blood vessels and nerves running over the superficial fascia.

A prominent **bone structure** on the medial surface is the sustentaculum tali that is always palpable about 2.5 cm below the tip of the medial malleolus<sup>(30)</sup>, similarly as the superior corner of the calcaneal tuberosity. With medial exposure, the neurovascular bundle (the posterior tibial vessels and the tibial nerve) must be sufficiently mobilized to allow adequate reduction and stabilization of the sustentaculum tali that is considered in this respect as the key structure.<sup>(4)</sup>

**Innervation** is ensured by the tibial nerve that splits into two branches to supply sensation to the skin of the medial heel and the medial foot sole<sup>(13)</sup> (Fig. 2.9.). The calcaneal branches perforate the superficial fascia at different levels<sup>(13)</sup> and run towards the bone. They are at risk with medial exposure of the calcaneus particularly if the dissection is carried too far posterior.

As compared to the lateral surface, **blood supply** to the medial surface is without numerous anastomoses and is ensured by the master posterior tibial artery. This artery supplies soft tissues from the level of the inferior border of the medial malleolus and passes to the territory supplied by the medial plantar artery.

**The tendon** passing immediately posterior to the neurovascular bundle is the flexor hallucis longus which



**Fig. 2.8. Schematic line drawing of lateral (A) and posterior (B) ligaments of the ankle and subtalar joints**

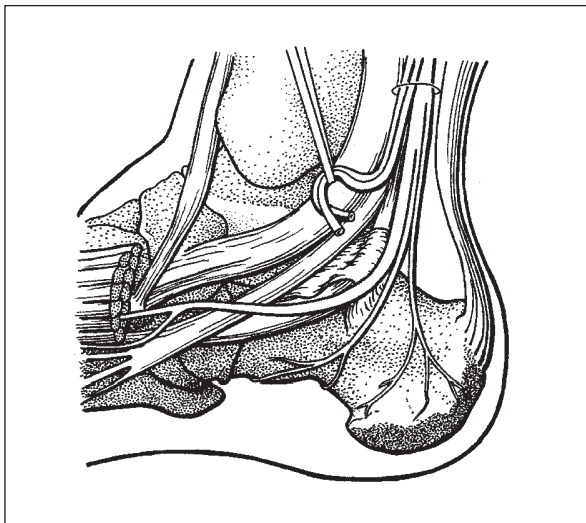


Fig. 2.9. Schematic line drawing of innervation of the medial aspect of the foot

runs in a fibrous tunnel beneath the sustentaculum tali. Anterior to the tendon of the flexor digitorum longus is the tendon of the posterior tibial tendon that passes over the deltoid ligament to its multiple insertions on the medial and plantar surfaces of the foot. The Achilles tendon is a thick, broad, easily identifiable structure getting thinner towards its insertion on the posterior and inferior two thirds of the calcaneus<sup>(28,30)</sup> (Fig. 2.10.).

Lying deeply to all the mentioned structures is a strong **ligamentous** structure, the deltoid ligament that usually remains intact in most fractures of the calcaneus, including its attachment to the superomedial fragment (Fig. 2.11.).

#### ■ Inferior surface

The skin on the sole is thick, covering the highly specialized layer of compartmentalized fibrofatty tissue (the heel pad) that is tightly fixed to the plantar surface and immobile (Fig. 2.12.). Particularly thanks to the perfect structure and tight fixation, the heel pad can absorb ex-

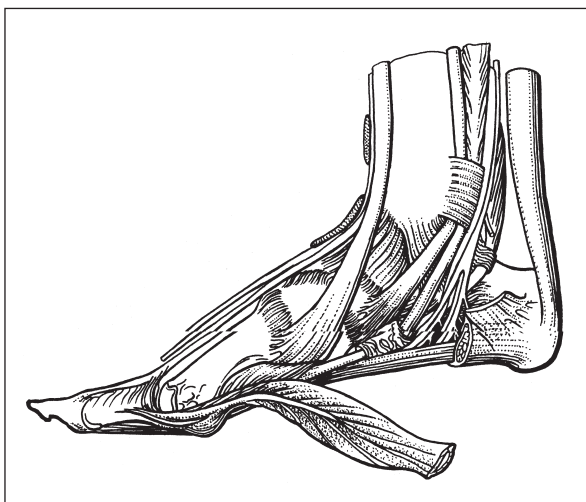


Fig. 2.10. Schematic line drawing of the course and attachments of tendons on the medial aspect of the foot

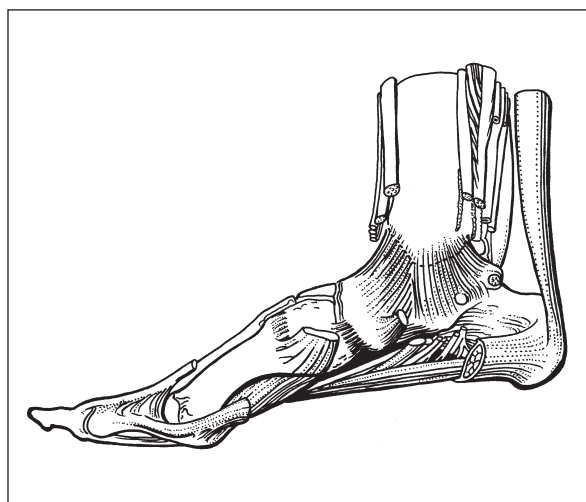


Fig. 2.11. Schematic line drawing of the medial aspect of the foot and ankle with the deltoid ligament

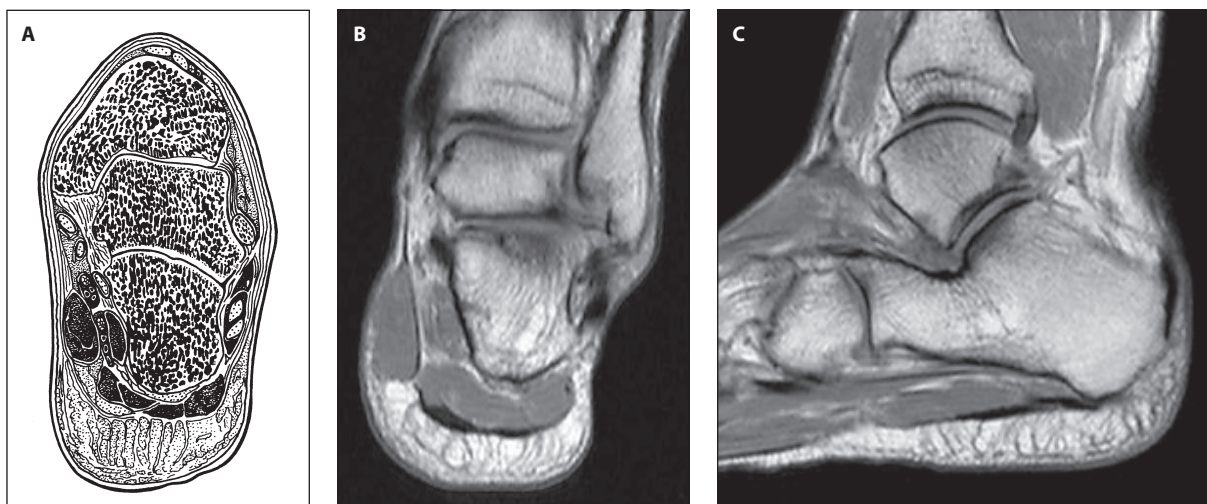


Fig. 2.12. Schematic line drawing of the coronal section of the tibial and talocalcaneal joints and soft structures of the sole (A), MRI of specialized fibrofatty tissue of the sole in the coronal (B) and sagittal planes (C)